



## UvA-DARE (Digital Academic Repository)

### Cardiac microvascular dysfunction

*Insights from COVID-19, myocardial infarction, and anthracycline-induced cardiotoxicity*

Jiang, Z.

#### Publication date

2026

[Link to publication](#)

#### Citation for published version (APA):

Jiang, Z. (2026). *Cardiac microvascular dysfunction: Insights from COVID-19, myocardial infarction, and anthracycline-induced cardiotoxicity*. [Thesis, fully internal, Universiteit van Amsterdam].

#### General rights

It is not permitted to download or to forward/distribute the text or part of it without the consent of the author(s) and/or copyright holder(s), other than for strictly personal, individual use, unless the work is under an open content license (like Creative Commons).

#### Disclaimer/Complaints regulations


If you believe that digital publication of certain material infringes any of your rights or (privacy) interests, please let the Library know, stating your reasons. In case of a legitimate complaint, the Library will make the material inaccessible and/or remove it from the website. Please Ask the Library: <https://uba.uva.nl/en/contact>, or a letter to: Library of the University of Amsterdam, Secretariat, P.O. Box 19185, 1000 GD Amsterdam, The Netherlands. You will be contacted as soon as possible.

# Chapter 3

## Atrial inflammation and microvascular thrombogenicity are increased in deceased COVID-19 patients

Linghe Wu *MSc*, Zhu Jiang *MEng*, Eva R. Meulendijks *MSc*, Umit Baylan *MSc*, Ingeborg S.E. Waas *BSc*, Marianna Bugiani *MD PhD*, Pieter R. Tuinman *MD PhD*, Judith Fronczek *MD, PhD*, Leo M.A. Heunks *MD PhD*, Joris R. de Groot *MD PhD*, Albert C. van Rossum *MD PhD*, Hans W. M. Niessen *MD PhD*, Paul A.J. Krijnen *PhD*

**Running title:** Atrial inflammation and microthrombi in COVID-19



**Published in :**

*Cardiovascular Pathology*. Volume 64, May-June 2023, 107524.

1

2

3

4

5

6

7

8

9

10

## Abstract

**Background** Histopathological studies have shown inflammation, cardiomyocyte injury and microvascular thrombosis in the ventricular myocardium of patients with coronavirus disease 2019 (COVID-19). However, although atrial dysfunction is common in COVID-19, little is known about histopathological changes in the atria of the heart. We therefore analysed inflammation, cardiomyocyte injury and microvascular thrombogenicity in the atria of deceased patients with COVID-19.

**Methods** Atrial tissue was obtained from autopsied COVID-19 ( $n=16$ ) patients and control patients ( $n=10$ ) and analysed using immunohistochemistry. The infiltration of CD45+ leukocytes, CD3+ T lymphocytes, CD68+ macrophages, MPO+ neutrophils and Tryptase+ mast cells were quantified as well as cardiomyocyte damage and microvascular thrombosis. In addition, Tissue Factor (TF) and Factor XII (FXII) were quantified as markers of microvascular thrombogenicity.

**Results** The numbers of lymphocytes, macrophages and neutrophils were significantly increased in the atrial myocardium and epicardial atrial adipose tissue of COVID-19 patients compared with the control group. This was accompanied by dispersed cardiomyocyte injury, the occasional presence of microvascular thrombosis and an increased presence of TF and FXII in the microvascular endothelium.

**Conclusions** Severe COVID-19 induces inflammation, cardiomyocyte injury and microvascular thrombosis in the atria of the heart.

**Keywords:** First and second wave COVID-19; Atria; Inflammation; Thrombi; Coagulation factors

## Highlights:

- Inflammation, cardiomyocyte injury and microvascular thrombosis are increased in the atria of the heart in COVID-19 patients.
- The increased inflammation and thrombogenicity are found both in the atrial myocardium and adipose tissue.
- In contrast to previous observations in the ventricles, the cardiac pathology of the atria remains high also in second wave COVID-19 patients.

## 1. Introduction

Cardiac involvement in coronavirus disease 2019 (COVID-19) has been well established. Multiple studies have reported elevated blood levels of cardiac troponin T (cTnT) and N-terminal pro-brain natriuretic peptide (NT-proBNP) in up to 36% of hospitalized COVID-19 patients, indicative of cardiac injury and stress [1-3]. Moreover, COVID-19 patients with cardiac involvement have been shown to have a higher morbidity and mortality rate [4]. A multitude of studies has further characterized pathogenic tissue alterations in the hearts of COVID-19 patients. Herein, cardiomyocyte injury, increased cardiac inflammation and lymphocytic myocarditis, as well as microvascular angiopathy and thrombosis have been observed in the ventricles of the heart in autopsied COVID-19 patients [5-8], and in ventricular endomyocardial biopsies of living COVID-19 patients [9,10]. Moreover, scar formation and edema have been shown in the ventricular myocardium of patients with ongoing [3] and recovered COVID-19 [11], using cardiac magnetic resonance imaging. However, the atria of the heart in COVID-19 have been less well studied, notwithstanding atrial fibrosis resulting from atrial inflammation and cardiomyocyte injury could form a substrate for future atrial arrhythmias.

Atrial dysfunction nevertheless appears to be a common complication in COVID-19 pathophysiology. Multiple studies have reported on the occurrence of atrial arrhythmia in COVID-19 patients. Atrial arrhythmia, including atrial tachyarrhythmia, fibrillation and (atypical) flutter, have been detected in up to 16.5% of hospitalized COVID-19 patients, and found to be more common than ventricular arrhythmia [12-16]. Moreover, the incidence of new-onset atrial arrhythmia among hospitalized patients without previous history of atrial arrhythmia was 4% to 5% [15,16], pointing to COVID-19-induced atrial dysfunction.

Atrial arrhythmias in non-COVID-19 patients were previously shown to coincide with increased cellular and microvascular inflammation in the atrial myocardium as well as in the epicardial atrial adipose tissue <sup>[17,18]</sup>. Inline herewith, in a recent case report, increased lymphocyte infiltration, cardiomyocyte necrosis and stenosing microangiopathy were observed in the right atrium of a deceased COVID-19 patient<sup>[19]</sup>, indicating that pathological changes in patients with COVID-19 occur not only in the ventricles but also in the atria.

In this study therefore, we have analysed inflammation, cardiomyocyte injury, microvascular thrombosis and markers of increased microvascular thrombogenicity in the atrial myocardium and adipose tissue of COVID-19 patients. In addition, we have compared putative atrial pathological changes between patients who died during the first and second wave of the pandemic as we have shown previously that (in conjunction with increased use of corticosteroids) inflammation, injury and thrombogenicity in the ventricles were markedly lower in the second wave than first wave COVID-19 patients<sup>[20]</sup>.

## 2. Materials and Methods

### 2.1 Patients

All included patients were referred to the department of Pathology of the Amsterdam UMC for autopsy. Tissue obtained from the left and right atrium of in total 26 deceased patients were collected from biobank in Amsterdam UMC for this research: patients with clinically confirmed SARS-CoV-2 infection who died of severe COVID-19 ( $n=16$ ) and control patients who died of a cause not related to heart disease and who did not show any cardiac signs of cardiac disease at pathological examination ( $n=10$ ). COVID-19 patients who died in the first wave of the pandemic (March - April of 2020) were defined as wave 1 patients ( $n=6$ ), while COVID-19 patients who died in the second wave (between October and the end of December 2020) were defined as wave 2 patients ( $n=10$ ). All control patients died at least a year before the start of the COVID-19 pandemic. The general histopathological and immunological findings of the first wave of COVID-19 patients were previously published <sup>[8]</sup>. Moreover, all but one of the patients used in this study were included in a previous publication describing detailed histopathological findings in the ventricles of the heart<sup>[20]</sup>. For all autopsies, the

tissue was obtained within 24 hours after death and immediately fixed in formalin and then embedded in paraffin.

This study was approved by the ethical committee at Amsterdam UMC, location VUmc (Amsterdam, the Netherlands), and conforms to the principles of the Declaration of Helsinki. The use of autopsy material for research after completion of the diagnostic process was consented in all cases.

## 2.2 Immunohistochemistry

Transmural slide-mounted tissue sections (4  $\mu\text{m}$ ) including the epicardial adipose tissue were used for analyses. Endogenous peroxidases were blocked with 0.3%  $\text{H}_2\text{O}_2$  in methanol for 30 minutes. Antigen retrieval was performed either by heat inactivation in Citrate buffer (pH=6.0; for CD68, CD3, MPO, Tryptase, C3d stainings), Tris-EDTA buffer (pH=9.0; for CD31 and tissue factor (TF) stainings) or enzymatically in 0.1% pepsin (37°C for 30 minutes; for factor XII (FXII) stainings). No antigen retrieval was performed for CD45 stainings. Primary antibodies were added for 1 hour at room temperature (RT): mouse-anti-human CD45 (1:100, Dako Santa Clara, USA; M0701), rabbit-anti-human CD68 (1:400, Dako M0814), rabbit-anti-human CD3 (1:100, Dako A0452), rabbit-anti-human MPO (myeloperoxidase, 1:500, Dako, A0398), mouse-anti-human Tryptase (1:100, Dako, M7052), rabbit-anti-human C3d (1:10000, Dako, A0063), mouse-anti-human CD31 (1:50, Dako; M0823), mouse-anti-human TF (1:250, Biorbyt Cambridge, UK; ORB100189), mouse-anti-human FXII (1:25, Sanquin). After a wash in PBS, the slides were incubated with goat-anti-rabbit/mouse Envision secondary antibodies (undiluted, Dako; K5007) for 30 minutes at RT. The stainings were visualized using 3,3'-diaminobenzidine (DAB) (0.1mg/mL, Dako) for 10 minutes and counterstained with hematoxylin for 1 minute. For each staining, slides incubated without a primary antibody were included as a negative control and these slides were found to be negative (data not shown).

## 2.3 Immunopathological and immunohistochemical analyses

All slides were analysed using light microscopy (Zeiss, Germany, 200 $\times$  magnification). For all analyses we have analysed one transmural tissue sample from the left and one from the right atrium (approximately 1 cm<sup>2</sup> area each) including epicardial adipose and myocardium tissue. The numbers of extravascular CD45<sup>+</sup> (leucocytes), CD3<sup>+</sup> (T lymphocytes), CD68<sup>+</sup> (macrophages), MPO<sup>+</sup>

(neutrophils) and Tryptase+ (mast cells) were counted in the myocardium and the adipose tissue of the atria separately. Only the CD45+ cells that were round with scant cytoplasm and showed a distinct peripheral reactivity for CD45 were counted<sup>[21]</sup>. In addition, the numbers of blood vessels wherein TF and FXII were present in/on the endothelium were counted in the myocardium and adipose tissue separately. The surface areas of the tissues were determined on scanned slides using a PathScan Enabler IV slide scanner (Meyer Instruments, Houston, TX, USA) and QuickPhoto Microanalysis software (Promicra, Prague, Czech Republic). For all markers, the numbers of positive blood vessels or cells were divided by the surface areas of the analysed tissues and calculated per mm<sup>2</sup>. Immunoscoring was performed by 3 independent researchers (L.W., P.A.J.K. and H.W.M.N.) and the inter-observation variation was below 10%. The presence of microthrombi was assessed on H&E-stained slides and CD31-stained slides. Cardiomyocyte death was identified on complement factor C3d-stained slides. In addition, myocarditis was defined as multiple foci inflammatory infiltrate associated with myocyte injury<sup>[6,20]</sup>.

### 2.4 Statistical analysis

All statistical analysis was performed with SPSS (version 26.0, Armonk, NY, USA). All figures were made by GraphPad Prism software version 9.0 (San Diego, CA, USA). Differences between the two groups were evaluated by Student t-test with Welch's correction or Mann-Whitney U test for Gaussian or non-Gaussian distributed data respectively. Comparisons between multiple groups (more than two) were evaluated by either a one-way ANOVA or Kruskal-Wallis test with post hoc Tukey's or Dunn's multiple comparisons for respectively Gaussian or non-Gaussian distributed data. Differences in semi-quantitatively determined myocardial inflammation, as well as frequency distributions of non-parametric variables between patient groups, were analysed with Fisher's exact test. P-values <0.05 were considered statistically significant.

## 3. Results

### 3.1 Pathologically defined patient groups

The characteristics of the control ( $n=10$ ), and COVID-19 patients ( $n=16$ ; wave 1:  $n=6$  and wave 2:  $n=10$ ) are presented in **Table 1**. All COVID-19 patients were hospitalized. The sex distribution did not differ significantly between control and COVID-19

patients. The average age of the COVID-19 patients ( $p=0.0048$ ) and wave 2 COVID-19 patients ( $p=0.0026$ ) was significantly higher compared with the control group.

**Table 1. Baseline patient characteristics**

Characteristic	Control	COVID-19		
		Total	Wave 1	Wave 2
<i>n</i>	10	16	6	10
Sex, male/female (%)	6/4 (60/40)	11/5 (69/31)	5/1 (83/17)	6/4 (60/40)
Age, years mean ( $\pm$ SD)	49 ( $\pm$ 13)	69 ( $\pm$ 13)**	68 ( $\pm$ 14)	72 ( $\pm$ 14)**
<b>Comorbidities <i>n</i> (%)</b>				
Hypertension	3 (30)	1 (6)	1 (17)	0 (0)
Arrhythmia	n.k.	/	0 (0)	n.k.
Pulmonary disease	n.k.	0 (0)	0 (0)	0 (0)
Cardiac ischemia	n.k.	3 (19)	2 (33)	1 (10)
CHF	n.k.	0 (0)	0 (0)	0 (0)
Diabetes	0 (0)	0 (0)	0 (0)	0 (0)
Active Malignancy	n.k.	2 (13)	1 (17)	1 (10)
Neurologic	n.k.	5 (31)	2 (33)	3 (30)
<b>Post-mortem diagnosed</b>				
LM	0 (0)	4 (25)	4 (67)	0 (0)
DCI	0 (0)	12 (75)	2 (33)##	10 (100)
<b>Thrombotic events <i>n</i> (%)</b>				
Deep vein thrombosis	0 (0)	4 (25)	3 (50)	1 (10)
Pulmonary embolism	0 (0)	9 (56)	3 (50)	6 (60)

COVID-19 indicates patients with PCR-proven SARS-CoV-2 infection-related disease. COVID-19 patients who died between March and April 2020 were defined as the first wave of pandemic (wave 1) patients, while COVID-19 patients who died between October and the end of 2020 were defined as the second wave of pandemic (wave 2) patients. Control indicates patients who died at least one year before the start of the COVID-19 pandemic, did not have any form of heart disease and did not have inflammation and/ or thrombosis of the atria tissue ( $n=10$ ).

CHF means congestive heart failure; LM means lymphocytic myocarditis; DCI means diffuse cardiac inflammation; n.k. means not known, i.e. the information is not retrievable. Frequency distributions were analyzed with Fisher's exact tests and age differences were analyzed with a Mann-Whitney U test. \*\* $p<0.01$  compared with the control group, ## $p<0.01$  between the first and second wave COVID-19

The autopsy findings related to the cause of death are shown in **Table 2**. All COVID-19 patients showed increased inflammation in the ventricles, which was diagnosed as lymphocytic inflammation (LM) in 4 patients (25%) and as diffuse cardiac inflammation (DCI) in 12 patients (75%), where it manifested as a dispersed mixed infiltration of lymphocytes and macrophages<sup>[20]</sup>. LM was present only in wave 1 patient, whereas DCI was present significantly more often in wave 2 patients

( $p=0.0082$ ). Pulmonary embolism and deep vein thrombosis were prevalent in COVID-19 patients, being observed in 4 (25%) and 9 (56%) of patients respectively, indicative of increased systemic thrombogenicity. No endocardial thrombi were found in the lumen of the atria of any of the COVID-19 patients. Overt dilation of the atria or other remarkable macroscopical findings were not observed.

**Table 2. The cause of death**

COVID-19 (n=16)	Cause of death
<b>Wave 1 (n=6)</b>	
#1	COVID-19 pneumonia with lymphocytic myocarditis with intramyocardial thrombi
#2	COVID-19 pneumonia with lymphocytic myocarditis with intramyocardial thrombi
#3	COVID-19 pneumonia with sepsis and lymphocytic myocarditis
#4	COVID-19 pneumonia with cerebral inflammation (COVID-19 related)
#5	COVID-19 pneumonia with lymphocytic myocarditis and recent myocardial infarction
#6	COVID-19 pneumonia with lymphocytic myocarditis with intramyocardial thrombi and hypoxic encephalopathy
<b>Wave 2 (n=10)</b>	
#1	COVID-19 pneumonia
#2	COVID-19 pneumonia with massive pulmonary thromboembolism
#3	COVID-19 pneumonia
#4	COVID-19 pneumonia with a recent myocardial infarction with a rupture of the ventricle wall
#5	COVID-19 pneumonia
#6	COVID-19 pneumonia with a recent myocardial infarction
#7	COVID-19 pneumonia
#8	COVID-19 pneumonia and massive pulmonary thromboembolism
#9	COVID-19 pneumonia with a recent myocardial infarction
#10	COVID-19 pneumonia
<b>Control (n=10)</b>	
#1	Car accident with rupture of the aorta
#2	Cerebral hemorrhage
#3	Bronchopneumonia
#4	Unknown cause of death
#5	Anaphylactic shock
#6	Cerebral infarction
#7	Unknown cause of death
#8	Dissection of the aorta
#9	Gastro-intestinal hemorrhage due to ruptured duodenal ulcer/ulcers
#10	Cerebral hemorrhage

ECG data was available only from 7 of the included COVID-19 patients. In 4 out of these 7 patients (57%) atrial fibrillation (AF) was recorded. In 2 patients without AF the ECG was normal, while in one non-AF patient right bundle branch block was observed (**Supplementary Table 1**).

### 3.2 Inflammation is increased in the atria of COVID-19 patients

In COVID-19 patients CD45+ leukocytes (**Figure 1A**), CD3+ T lymphocytes (**Figure 1B**), CD68+ macrophages (**Figure 1C**), MPO+ neutrophils (**Figure 1D**) and mast cells (**Figure 1E**) were present diffusely throughout the atrial tissue, both in the myocardium as well as in the epicardial adipose tissue. In control patients only very low numbers of these inflammatory cells were counted (**Figure 2**). In COVID-19 patients however, the numbers of CD45+ cells/mm<sup>2</sup> (**Figure 2A**;  $p < 0.01$ ), CD3+ cells/mm<sup>2</sup> (**Figure 2B**;  $p < 0.01$ ), CD68+ cells/mm<sup>2</sup> (**Figure 2C**;  $p < 0.001$ ) and MPO+ cells/mm<sup>2</sup> (**Figure 2D**,  $p < 0.01$ ) were significantly increased compared with control patients. Macrophages showed the most numerous increases as their numbers were over 100-fold higher in COVID-19 patients than in controls. In contrast, the numbers of mast cells/mm<sup>2</sup> (**Figure 2E**) did not differ significantly between COVID-19 and control patients. The increased inflammation in COVID 19 compared to control patients was present both in the right and left atrium (not shown).

In previous studies, we have observed that atrial inflammation in AF patients was more prominent in the adipose tissue than in the myocardium [17,18]. We therefore compared the inflammatory infiltrate in COVID-19 patients between the myocardium and adipose tissue also. The observed significant increases in CD45+, CD3+, CD68+ and MPO+ cells/mm<sup>2</sup> in COVID-19 patients compared to controls, were present both in the myocardium (respectively  $p < 0.05$ ,  $p < 0.01$ ,  $p < 0.001$ ,  $p < 0.05$ ) and the epicardial adipose tissue (respectively  $p < 0.01$ ,  $p < 0.01$ ,  $p < 0.001$ ,  $p < 0.01$ ) (**Figures 2A-D**). However, no significant differences were observed between the numbers of any of the analysed inflammatory cells between the atrial myocardium and adipose tissue (**Figure 2A-E**).

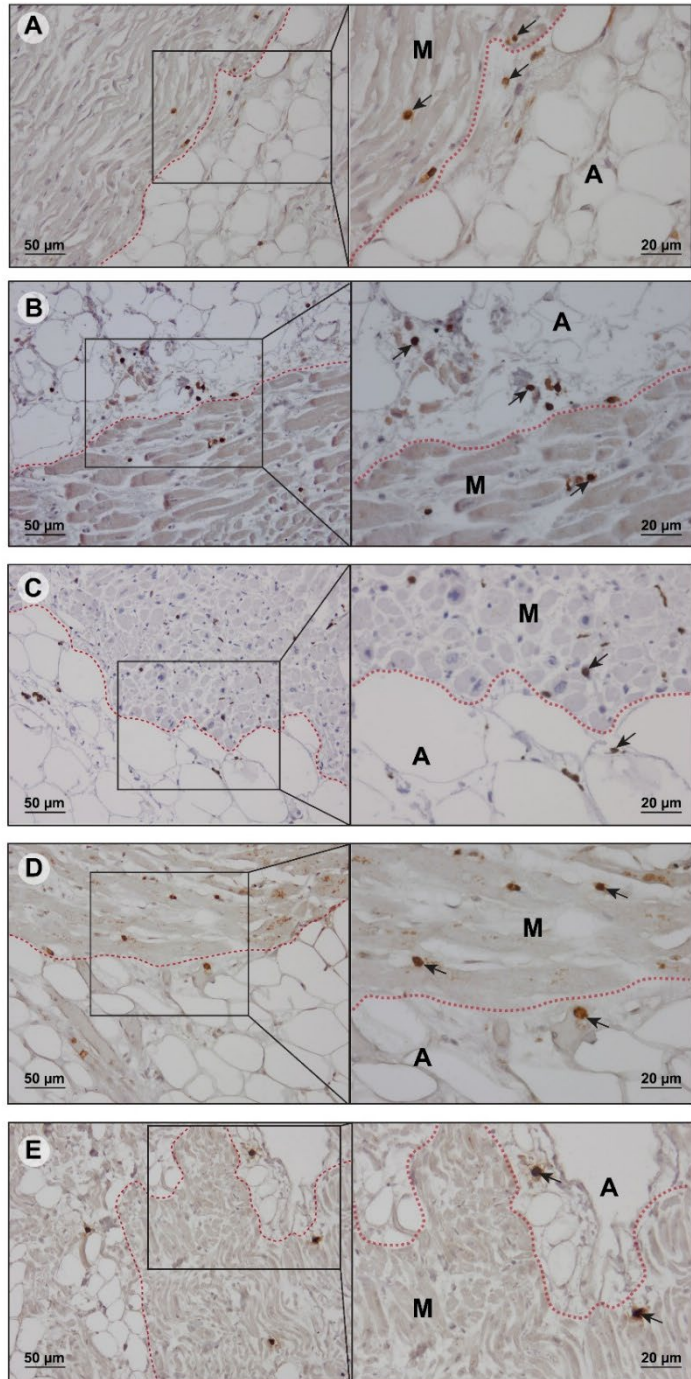
Lastly, recently we observed in these patients that inflammation in the ventricles of the heart was markedly lower in wave 2 patients than in wave 1 patients [20]. In contrast, the numbers of inflammatory cells were similar and there were no

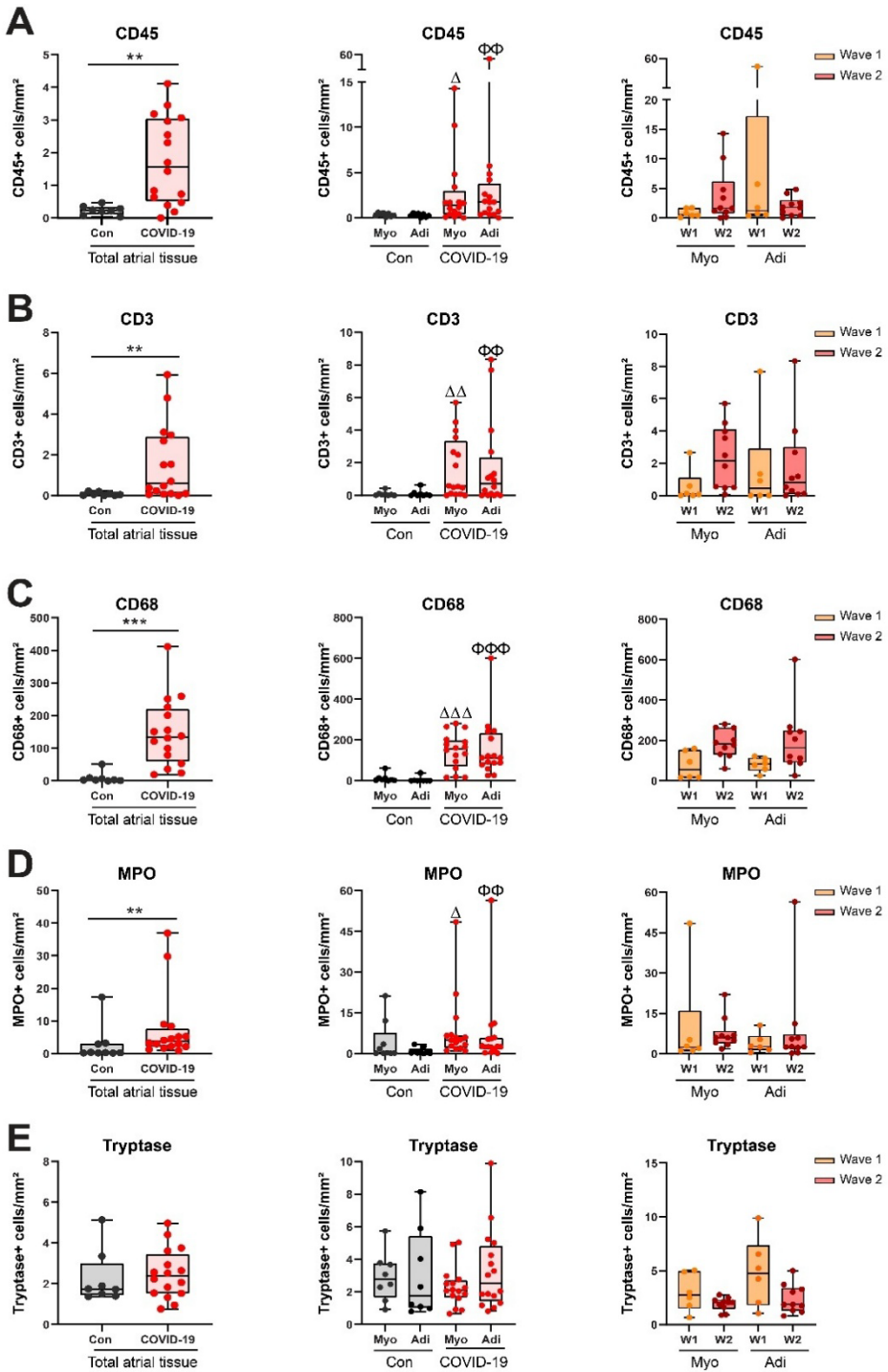
significant differences in the atrial myocardium nor the adipose tissue between wave 1 and wave 2 COVID-19 patients (**Figure 2A-E**).

**Figure. 1** Examples of immunohistochemical staining of CD45+ leukocytes (A), CD3+ T lymphocytes (B), CD68+ macrophages (C), MPO+ neutrophils (D) and Tryptase+ mast cells (E) (black arrows) in the atria of patients with COVID-19.

M: myocardium, A: adipose tissue.

Scar bar =50µm and 20µm.





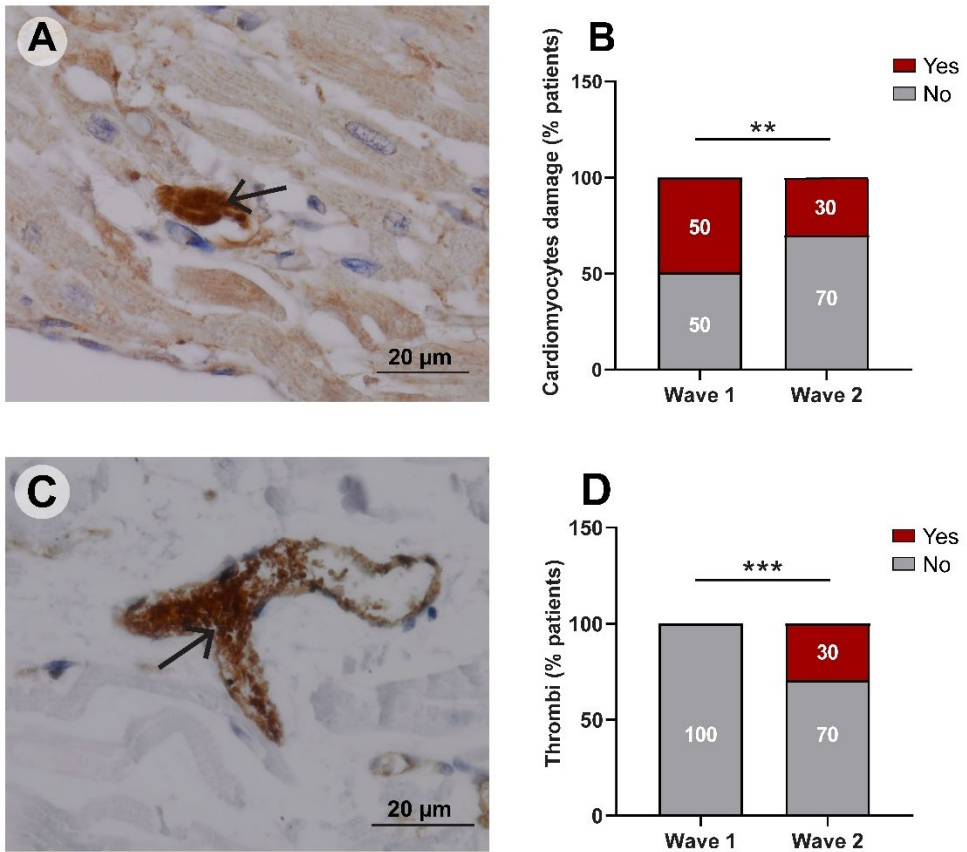
**Figure. 2** Inflammatory cells in the atria of control (Con, n=10) patients and COVID-19 (n=16) patients. Box-and-whisker plot depiction of the number of (A) CD45+ leukocytes (B) CD3+ T lymphocytes (C) CD68+ macrophages (D) MPO+ neutrophils and (E) Tryptase+ mast cells per mm<sup>2</sup> of the total atrial tissue per mm<sup>2</sup> of the total atrial tissue, as well as the myocardium (Myo) and the adipose tissue (Adi) separately, of control (Con, n=10)

and COVID-19 (n=16; wave 1, n=6; wave 2, n=10) patients. Each point represents the value of 1 individual patient, the bars represent mean  $\pm$  SD.  $\Delta$  means compared with the myocardium of the control group;  $\Phi$  means compared with adipose tissue of the control group.  $\Delta/\Phi$ /\*p<0.05,  $\Delta\Delta/\Phi\Phi$ /\*\*p<0.01,  $\Delta\Delta\Delta/\Phi\Phi\Phi$ /\*\*\*/p<0.001

### 3.3 Cardiomyocyte injury and increased microvascular thrombogenicity in the atria of COVID-19 patients

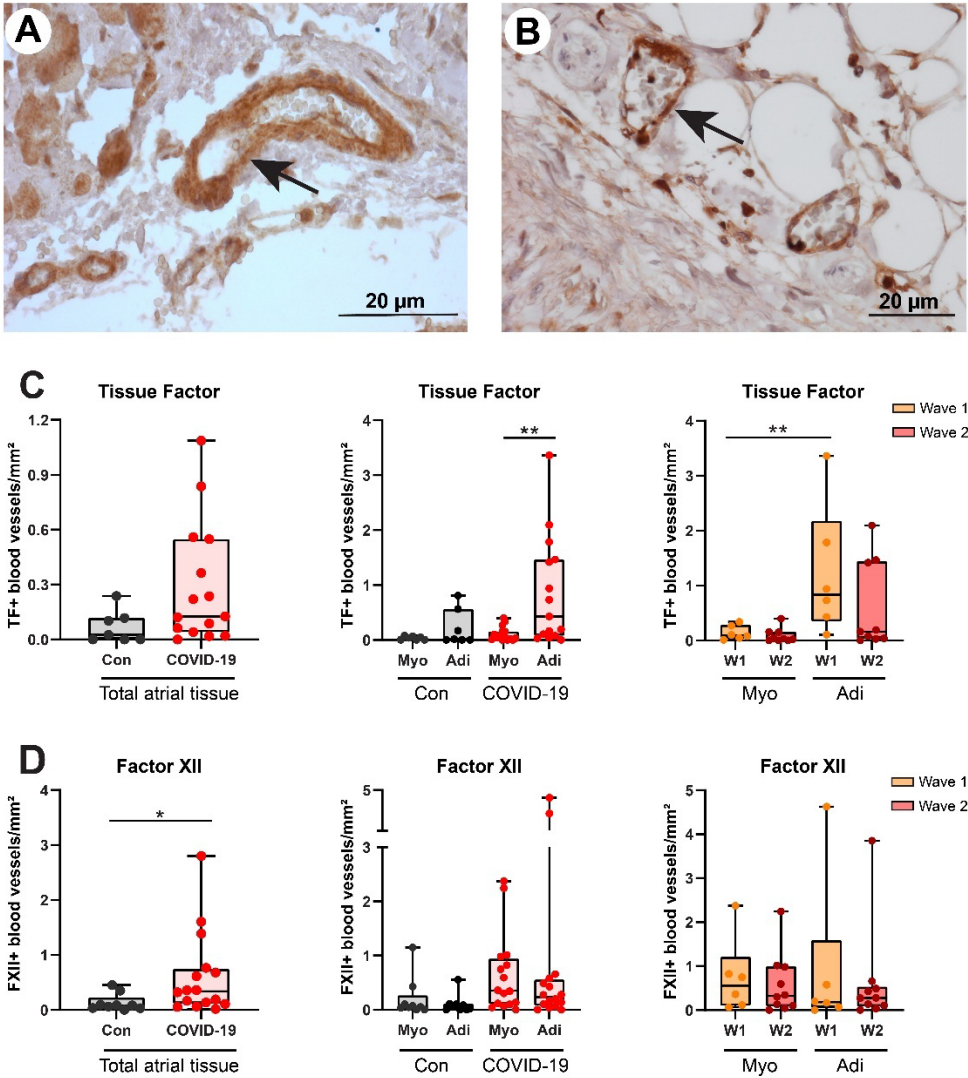
We then analysed whether the observed inflammation coincided with cardiomyocyte death in the atria. In control patients no cardiomyocyte death was observed. However, in COVID-19 patients cardiomyocyte death, objectified by complement factor C3d immunostaining, was observed in dispersed individual cells (**Figure 3A**). Notably, cardiomyocyte death occurred significantly more often in wave 1 patients (50%, 3 of 6) than in wave 2 patients (30 %, 3 of 10) (**Figure 3B**, p=0.006). Furthermore, we detected intravascular thrombi consisting of aggregated CD31+ platelets and fibrin within the myocardial microvasculature of the atria in three COVID-19 patients (**Figure 3C**), while no intravascular thrombi were found in control patients. These intravascular thrombi were all observed in wave 2 COVID-19 patients, while none were found in wave 1 patients (**Figure 3D**, p<0.001).

The presence of procoagulant factors TF and FXII in the atrial microvasculature was analysed also. Only blood vessels wherein the procoagulant factors were present on the endothelium were counted (**Figure 4A and 4B**). In control patients the numbers of TF+ and FXII+ blood vessels were low. In COVID-19 patients the number of TF+ blood vessels in the atria were higher than in controls, although not significantly (**Figure 4C**; p=0.067), while the number of FXII+ blood vessels were significantly higher than in controls (**Figure 4D**, p<0.05). The TF+ and FXII+ vessels were distributed throughout the myocardium and the adipose tissue. Interestingly, we observed significantly more TF+ vessels in the adipose tissue compared with the myocardium in COVID-19 patients', especially in wave 1 (**Figure 4C**, p<0.01), while for FXII the numbers were similar between myocardium and adipose tissue and between wave 1 and wave 2 (**Figure 4D**). Notably, the numbers of TF+ and FXII+ vessels did not differ significantly between COVID-19 patients with thrombi (n=3) and without thrombi (n=13).



**Figure. 3** (A) Immunohistochemical example of cardiomyocyte death (objectified with complement factor C3d) and (B) the percentage of patients wherein cardiomyocyte death was observed in wave 1 ( $n=6$ ) and wave 2 ( $n=10$ ) COVID-19 patients. (C) Immunohistochemical example of intravascular aggregated CD31+ platelets and fibrin, indicative of a microvascular thrombus in COVID-19 patients and (D) the percentage of patients wherein microvascular thrombi were observed in wave 1 ( $n=6$ ) and wave 2 ( $n=10$ ) COVID-19 patients. \*\* $p<0.01$ , \*\*\* $p<0.001$  were analysed by Fisher's exact test.

3



**Figure. 4** (A) An example of the presence of TF+ blood vessels and (B) FXII+ blood vessels in the atrial adipose tissue in COVID-19 patients. (C) The number of TF+ blood vessels and (D) the number of FXII+ blood vessels per mm<sup>2</sup> of the total atrial tissue, as well as the myocardium (Myo) and the adipose tissue (Adi) separately, of control (Con, n=10) and COVID-19 (n=16; wave 1, n=6; wave 2, n=10) patients. Scar bar=20um. Each point in the graphs represents the value of one individual patient, the bars represent mean ± SD. Δ means compared with the myocardium of the control group; Φ means compared with adipose tissue of the control group. \*p<0.05, \*\*p<0.01

## 4. Discussion

Atrial dysfunction is a relatively common complication in COVID-19. However, knowledge about histopathological changes in the atria in patients with COVID-19 is limited. In the present study, we observed significant increases in lymphocyte, macrophage and neutrophil infiltration, both in the myocardium and adipose tissue of the atria. In addition, dispersed cardiomyocyte injury, and microvascular thrombosis were present in part of the COVID-19 patients, as well as an increased presence of procoagulant factors in the microvascular endothelium.

The inflammation, cardiomyocyte injury and microvascular thrombosis we observed in the atria of COVID-19 patients are similar to those observed by us and others in the ventricles of the heart<sup>[2,5-8,20]</sup>. Remarkable was the 100-fold increase in diffuse interstitial macrophages in the atria. This corresponds to the previously observed high levels of diffuse macrophage infiltration in the ventricles in approximately 90% of autopsied COVID-19 patients<sup>[6,20]</sup>. Moreover, increases in specifically macrophages were previously noted in the ventricles of patients with SARS-CoV-1 infection<sup>[22,23]</sup>, indicating that cardiac macrophage infiltration may be a general feature of SARS-CoV infection, at least in severe cases. In addition, previous studies have shown increased numbers of CD68+ macrophages in the hearts of patients with chronic cardiac diseases such as ischemic heart disease<sup>[24]</sup> and amyloidosis<sup>[25]</sup>, as well as patients with sepsis<sup>[26]</sup>. The high numbers of infiltrated macrophages we observed in the atria of COVID-19 (up to 400+ per mm<sup>2</sup>) are especially comparable to those observed in the hearts of septic patients<sup>[26]</sup>, albeit these were quantified in the left ventricle.

As is true for the ventricles, the causes for these histopathological changes in the atria remain unclear and could include direct SARS-CoV-2 infection, increased systemic inflammation and coagulability, as well as hemodynamic changes. However, this remains to be elucidated. In addition, atrial inflammation may occur secondary to ventricular inflammation and disease, as was shown in patients with LM and stress myocarditis and myocardial infarction<sup>[18]</sup>. However, the decrease in ventricular inflammation we reported previously in wave 2 patients compared to wave 1 patients<sup>[20]</sup>, was not observed in the atria in the current study. Although cardiomyocyte injury occurred less frequently in wave 2 patients, inflammation and the presence of microvascular procoagulant factors were similar, while the occurrence of microvascular thrombosis was even higher than in wave 1 patients. It

thus appears unlikely that the atrial pathology we observed here is solely a result of COVID-19-associated ventricular pathology. Indeed, it was suggested that the resulting atrial tachyarrhythmia was related to the amount of atrial inflammation, rather than to COVID-19 exclusively<sup>[15]</sup>. Moreover, in said study we argued that the decreased ventricular pathology in wave 2 patients most likely resulted from advances in the clinical management of COVID-19, including the increased use of the corticosteroid dexamethasone in severely ill patients specifically. If this is true, our current study shows that the atria may respond differently to the clinical treatment than the ventricles. In addition, the prevalence of SARS-CoV-2 strain variants differed between the first and second wave<sup>[27]</sup>, which theoretically could be a contributing factor in the results of our study, although evidence for this so far is lacking.

The increase in atrial inflammation in COVID-19 patients may represent an arrhythmic substrate and predispose toward arrhythmia development and may, in part, explain the increased occurrence of atrial tachyarrhythmia, fibrillation and flutter in hospitalized COVID-19 patients<sup>[12-16]</sup>. Indeed, in our study atrial fibrillation was recorded in 4 out of the 7 patients from whom ECG data were available, albeit we do not know whether this was new-onset atrial fibrillation or not. However, also in patients recovered from COVID-19, such proarrhythmogenic substrate may predispose to late-onset atrial fibrillation and its consequences such as stroke and heart failure. Increased numbers of infiltrated lymphocytes, macrophages and neutrophils have been found in the atria of patients with atrial fibrillation (AF), especially in the atrial adipose tissue<sup>[17,18]</sup>. Recent studies point to the epicardial adipose tissue (EAT) as an important endocrine organ that affects cardiomyocyte and vascular function both in physiological and pathophysiological conditions also in the atria. For instance, EAT volume was shown to be associated with abnormal atrial conduction<sup>[28]</sup> and arrhythmia<sup>[29]</sup> and the inflammatory activity of EAT, as measured by 18-fluorodeoxyglucose (FDG) uptake in left atrial EAT, was found to be increased in AF patients<sup>[30]</sup>. Furthermore, significant EAT attenuation and increased density, a proposed sign of increased adipose tissue inflammation, was observed in patients with severe and critical COVID-19 using computed tomography (CT) imaging<sup>[31]</sup>, which is in line with the increased inflammatory cell density in the atrial adipose tissue we show here. However, dexamethasone therapy was found to associate with a reduction of this CT-observed EAT density, thus indicative of decreased EAT inflammation, in COVID-19 patients<sup>[32]</sup>. These results,

although in agreement with our previous findings in the ventricles<sup>[20]</sup>, do not concur with the persistent atrial inflammation in wave 2 COVID-19 patients we show here. Notably, in these studies the EAT density was determined at the mid-level of the left anterior descending coronary artery and thus in ventricular EAT, not in atrial EAT, and it was shown before that the transcriptome of EAT differs considerably depending on its anatomical location<sup>[33]</sup>. Interestingly, corticosteroid treatment was recently shown to associate with an increased risk of developing AF in hospitalized COVID-19 patients<sup>[34]</sup> and patients without pulmonary and cardiovascular diseases<sup>[35]</sup>. Whether this relates to the persistent atrial inflammation in our wave 2 COVID-19 patients remains to be elucidated. Unfortunately, atrial arrhythmias were not analysed in our patient cohort and hence we could not verify putative associations between the observed atrial pathology and the occurrence of arrhythmia.

A limitation of this study is the relatively small number of patients we could include. Moreover, all included COVID-19 patients died in 2020. Putative effects of later SARS-CoV-2 strains such as the alpha, delta and omicron variants, as well as vaccinations, were therefore not analysed. Moreover, we used atria tissue from patients who died from very severe COVID-19 and to what extent the atrial pathology we present here occurs in patients with less severe COVID-19 remains to be established. Similarly, we cannot comment on the potential reversibility and the sequelae of the inflammatory and structural changes we report here. Furthermore, the atria were sampled in one location only. We cannot exclude the possibility that the observed histopathological changes are heterogeneous and may differ between atrial locations. This notion should be considered when interpreting the current data. As ECG data was available only from the part of the already limited number of COVID-19 patients, the relation between the atrial pathology we describe here and atrial arrhythmias thus requires further study. Lastly, the average age of the control group was lower than the COVID-19 group, although we do not believe it likely that age was an important confounder in the observed atrial pathology we observed in the COVID-19 group.

In conclusion, our study shows the occurrence of cardiomyocyte death and increased inflammation and microvascular thrombogenicity in both the myocardium and adipose tissue of the atria in patients with COVID-19, which may impact atrial function and arrhythmogenesis, both during acute disease and during follow-up.

## **Acknowledgments of grant support:**

This work was supported by the China Scholarship Council (Beijing, China, Grant number: 201708260020 to LW, 202008320278 to JZ); Amsterdam UMC Corona Research Fund

## **Author contributions**

Author contributions are as follows: **LW, HN** and **PK** designed this study; **LW, ZJ, UB** and **IW** collected the tissue, and performed the experiments; **LW** and **ZJ** involved formal data analysis; **LW, HN** and **PK** compiled the original draft; **EM, MB, PT, LH, JF, JG, AR, HN** and **PK** contributed revision and critical appraisal for the final version of the manuscript. All authors approved the final draft submission.

## **Competing Interest**

The authors declare no competing interests.

## **Disclosure**

None

## References

- [1]. Lala A, Johnson KW, Januzzi JL, Russak AJ, Paranjpe I, Richter F, Zhao S, Somani S, Van Vleck T, Vaid A, et al. Prevalence and Impact of Myocardial Injury in Patients Hospitalized With COVID-19 Infection. *J Am Coll Cardiol*. 2020;76:533–546. doi: 10.1016/j.jacc.2020.06.007
- [2]. Pellegrini D, Kawakami R, Guagliumi G, Sakamoto A, Kawai K, Gianatti A, Nasr A, Kutys R, Guo L, Cornelissen A, et al. Microthrombi as a Major Cause of Cardiac Injury in COVID-19: A Pathologic Study. *Circulation*. 2021;143:1031–1042. doi: 10.1161/CIRCULATIONAHA.120.051828
- [3]. Inciardi RM, Lupi L, Zacccone G, Italia L, Raffo M, Tomasoni D, Cani DS, Cerini M, Farina D, Gavazzi E, et al. Cardiac Involvement in a Patient With Coronavirus Disease 2019 (COVID-19). *JAMA Cardiol*. 2020;5:819–824. doi: 10.1001/jamacardio.2020.1096
- [4]. Guan WJ, Ni ZY, Hu Y, Liang WH, Ou CQ, He JX, Liu L, Shan H, Lei CL, Hui DSC, et al. Clinical Characteristics of Coronavirus Disease 2019 in China. *N Engl J Med*. 2020;382:1708–1720. doi: 10.1056/NEJMoa2002032
- [5]. Wichmann D, Sperhake JP, Lutgehetmann M, Steurer S, Edler C, Heinemann A, Heinrich F, Mushumba H, Kniep I, Schroder AS, et al. Autopsy Findings and Venous Thromboembolism in Patients With COVID-19: A Prospective Cohort Study. *Ann Intern Med*. 2020;173:268–277. doi: 10.7326/M20-2003
- [6]. Basso C, Leone O, Rizzo S, De Gaspari M, van der Wal AC, Aubry MC, Bois MC, Lin PT, Maleszewski JJ, Stone JR. Pathological features of COVID-19-associated myocardial injury: a multicentre cardiovascular pathology study. *Eur Heart J*. 2020;41:3827–3835. doi: 10.1093/eurheartj/ehaa664
- [7]. Bois MC, Boire NA, Layman AJ, Aubry MC, Alexander MP, Roden AC, Hagen CE, Quinton RA, Larsen C, Erben Y, et al. COVID-19-Associated Nonocclusive Fibrin Microthrombi in the Heart. *Circulation*. 2021;143:230–243. doi: 10.1161/CIRCULATIONAHA.120.050754
- [8]. Schurink B, Roos E, Radonic T, Barbe E, Bouman CSC, de Boer HH, Bulle EB, Aronica EM, Florquin S, et al. Viral presence and immunopathology in patients with lethal COVID-19: a prospective autopsy cohort study. *The Lancet Microbe*. 2020;1:e290–e299. doi: 10.1016/s2666-5247(20)30144-0
- [9]. Sala S, Peretto G, Gramegna M, Palmisano A, Villatore A, Vignale D, De Cobelli F, Tresoldi M, Cappelletti AM, Basso C, et al. Acute myocarditis presenting as a reverse Tako-Tsubo syndrome in a patient with SARS-CoV-2 respiratory infection. *Eur Heart J*. 2020;41:1861–1862. doi: 10.1093/eurheartj/ehaa286
- [10]. Escher F, Pietsch H, Aleshcheva G, Bock T, Baumeier C, Elsaesser A, Wenzel P, Hamm C, Westenfeld R, Schultheiss M, et al. Detection of viral SARS-CoV-2 genomes and histopathological changes in endomyocardial biopsies. *ESC Heart Fail*. 2020;7:2440–2447. doi: 10.1002/ehf2.12805
- [11]. Puntmann VO, Carerj ML, Wieters I, Fahim M, Arendt C, Hoffmann J, Shchendrygina A, Escher F, Vasa-Nicotera M, Zeiher AM, et al. Outcomes of Cardiovascular Magnetic Resonance Imaging in Patients Recently Recovered From Coronavirus Disease 2019 (COVID-19). *JAMA Cardiol*. 2020;5:1265–1273. doi: 10.1001/jamacardio.2020.3557
- [12]. Colon CM, Barrios JG, Chiles JW, McElwee SK, Russell DW, Maddox WR, Kay GN. Atrial Arrhythmias in COVID-19 Patients. *JACC Clin Electrophysiol*. 2020;6:1189–1190. doi: 10.1016/j.jacep.2020.05.015
- [13]. Pimentel M, Magalhaes APA, Novak CV, May BM, Rosa L, Zimerman LI. Cardiac Arrhythmias in Patients with COVID-19. *Arq Bras Cardiol*. 2021. doi: 10.36660/abc.20200963
- [14]. Mesquita D, Carmo P, Cabanelas N, Santos N, Martins V, Sanfins V, Costa HC, Fontes JP, Fonseca P, Parreira L, et al. Cardiac arrhythmias in patients presenting with COVID-19 treated in Portuguese hospitals: A national registry from the Portuguese Association of Arrhythmology, Pacing and Electrophysiology. *Rev Port Cardiol*. 2021;40:573–580. doi: 10.1016/j.repc.2020.11.007
- [15]. Musikantow DR, Turagam MK, Sartori S, Chu E, Kawamura I, Shivamurthy P, Bokhari M, Oates C, Zhang C, Pumill C, et al. Atrial Fibrillation in Patients Hospitalized With COVID-19: Incidence, Predictors, Outcomes, and Comparison to Influenza. *JACC Clin Electrophysiol*. 2021;7:1120–1130. doi: 10.1016/j.jacep.2021.02.009
- [16]. Kelesoglu S, Yilmaz Y, Ozkan E, Catapkorur B, Gok M, Dursun ZB, Kilic AU, Demirelli S, Simsek Z, Elcik D. New onset atrial fibrillation and risk factors in COVID-19. *J Electrocardiol*. 2021;65:76–81. doi: 10.1016/j.jelectrocard.2020.12.005
- [17]. Wu L, Emmens RW, van Wezenbeek J, Stooker W, Allaart CP, Vonk ABA, van Rossum AC, Niessen HWM, Krijnen PAJ. Atrial inflammation in different atrial fibrillation subtypes and its relation with clinical risk factors. *Clin Res Cardiol*. 2020;109:1271–1281. doi: 10.1007/s00392-020-01619-8

- [18]. Begieneman MP, Emmens RW, Rijvers L, Kubat B, Paulus WJ, Vonk AB, Rozendaal L, Biesbroek PS, Wouters D, Zeerleder S, et al. Ventricular myocarditis coincides with atrial myocarditis in patients. *Cardiovasc Pathol.* 2016;25:141–148. doi: 10.1016/j.carpath.2015.12.001
- [19]. Goette A, Patscheke M, Henschke F, Hammwohner M. COVID-19-Induced Cytokine Release Syndrome Associated with Pulmonary Vein Thromboses, Atrial Cardiomyopathy, and Arterial Intima Inflammation. *TH Open.* 2020;4:e271–e279. doi: 10.1055/s-0040-1716717
- [20]. Wu L, Baylan U, van der Leeden B, Schurink B, Roos E, Schalkwijk CG, Bugiani M, van der Valk P, van Rossum AC, Zeerleder SS, et al. Cardiac inflammation and microvascular procoagulant changes are decreased in second wave compared to first wave deceased COVID-19 patients. *Int J Cardiol.* 2021. doi: 10.1016/j.ijcard.2021.11.079
- [21]. Wu L, Woudstra L, Dam TA, Germans T, van Rossum AC, Niessen HWM, Krijnen PAJ. Electrocardiographic changes are strongly correlated with the extent of cardiac inflammation in mice with Cocksackievirus B3-induced viral myocarditis. *Cardiovasc Pathol.* 2021:107367. doi: 10.1016/j.carpath.2021.107367
- [22]. Oudit GY, Kassiri Z, Jiang C, Liu PP, Poutanen SM, Penninger JM, Butany J. SARS-coronavirus modulation of myocardial ACE2 expression and inflammation in patients with SARS. *Eur J Clin Invest.* 2009;39:618–625. doi: 10.1111/j.1365-2362.2009.02153.x
- [23]. Fox SE, Falgout L, Vander Heide RS. COVID-19 myocarditis: quantitative analysis of the inflammatory infiltrate and a proposed mechanism. *Cardiovasc Pathol.* 2021;54:107361. doi: 10.1016/j.carpath.2021.107361
- [24]. Azzawi M, Kan SW, Hillier V, Yonan N, Hutchinson IV, Hasleton PS. The distribution of cardiac macrophages in myocardial ischaemia and cardiomyopathy. *Histopathology.* 2005;46:314–319. doi: 10.1111/j.1365-2559.2005.02075.x
- [25]. Stats MA, Stone JR. Varying levels of small microcalcifications and macrophages in ATTR and AL cardiac amyloidosis: implications for utilizing nuclear medicine studies to subtype amyloidosis. *Cardiovasc Pathol.* 2016;25:413–417. doi: 10.1016/j.carpath.2016.07.001
- [26]. Rossi MA, Celes MR, Prado CM, Saggiaro FP. Myocardial structural changes in long-term human severe sepsis/septic shock may be responsible for cardiac dysfunction. *Shock.* 2007;27:10–18. doi: 10.1097/01.shk.0000235141.05528.47
- [27]. Hodcroft EB, Zuber M, Nadeau S, Vaughan TG, Crawford KHD, Althaus CL, Reichmuth ML, Bowen JE, Walls AC, Corti D, et al. Spread of a SARS-CoV-2 variant through Europe in the summer of 2020. *Nature.* 2021;595:707–712. doi: 10.1038/s41586-021-03677-y
- [28]. Friedman DJ, Wang N, Meigs JB, Hoffmann U, Massaro JM, Fox CS, Magnani JW. Pericardial fat is associated with atrial conduction: the Framingham Heart Study. *J Am Heart Assoc.* 2014;3:e000477. doi: 10.1161/JAHA.113.000477
- [29]. Wong CX, Ganesan AN, Selvanayagam JB. Epicardial fat and atrial fibrillation: current evidence, potential mechanisms, clinical implications, and future directions. *Eur Heart J.* 2017;38:1294–1302. doi: 10.1093/eurheartj/ehw045
- [30]. Mazurek T, Kiliszek M, Kobylecka M, Skubisz-Gluchowska J, Kochman J, Filipiak K, Kroticki L, Opolski G. Relation of proinflammatory activity of epicardial adipose tissue to the occurrence of atrial fibrillation. *Am J Cardiol.* 2014;113:1505–1508. doi: 10.1016/j.amjcard.2014.02.005
- [31]. Iacobellis G, Secchi F, Capitanio G, Basilico S, Schiaffino S, Boveri S, Sardanelli F, Corsi Romanelli MM, Malavazos AE. Epicardial Fat Inflammation in Severe COVID-19. *Obesity (Silver Spring).* 2020;28:2260–2262. doi: 10.1002/oby.23019
- [32]. Iacobellis G, Malavazos AE, Basilico S, Tresoldi S, Rinaldo RF, Dubini C, Capitanio G, Serpi F, Schiaffino S, Oliva OA, et al. Epicardial fat inflammation response to COVID-19 therapies. *Obesity (Silver Spring).* 2021;29:1427–1433. doi: 10.1002/oby.23232
- [33]. Gaborit B, Venticlef N, Ancel P, Pelloux V, Gariboldi V, Leprince P, Amour J, Hatem SN, Jouve E, Dutour A, et al. Human epicardial adipose tissue has a specific transcriptomic signature depending on its anatomical peri-atrial, peri-ventricular, or peri-coronary location. *Cardiovasc Res.* 2015;108:62–73. doi: 10.1093/cvr/cvv208
- [34]. Lee Y, Jehangir Q, Poisson L, Latack K, Krishnamoorthy G, Sule A, Song S, Apala DR, Halabi AR, Patel K. Corticosteroids and the Risk of Atrial Fibrillation in Hospitalized COVID-19 Patients. *Circulation.* 2021;144:A13683–A13683.
- [35]. Christiansen CF, Christensen S, Mehnert F, Cummings SR, Chapurlat RD, Sorensen HT. Glucocorticoid use and risk of atrial fibrillation or flutter: a population-based, case-control study. *Arch Intern Med.* 2009;169:1677–1683. doi: 10.1001/archinternmed.2009.297

**Supplementary Table 1. Medical data**

<b>Patients</b>	<b>ECG findings</b>	<b>Echocardiography</b>	<b>ECMO/ PCI</b>	<b>Therapeutic management</b>
1	- AF	n.a.	no	<i>antibiotic</i> ciproxin <i>immunosuppressant</i> chloroquine <i>anti-retroviral</i> lopinavir/ritonavir <i>anti-arrhythmic</i> amiodarone <i>beta blockers</i> metoprolol
2	- AF - 1 <sup>st</sup> degree AV- block - Broad complex escape rhythm	global normal function	no	<i>antibiotics</i> ciproxin/ceftriaxone <i>anti-coagulants</i> heparin CVVHD
3	n.a.	n.a.	no	<i>antibiotics</i> vancomycin/meromycin <i>immunosuppressant</i> sirolimus
4	normal	n.a.	no	<i>immunosuppressant</i> prednisolone
5	normal	n.a.	no	<i>immunosuppressant</i> prednisone <i>anti-coagulants</i> heparin
6	- AF - Possible ectopic atrial rhythm - Inferior Q and low R in anterior leads	n.a.	no	<i>immunosuppressant</i> chloroquine <i>anti-coagulants</i> heparin <i>beta blockers</i> metoprolol  Of note: IHCA due to tension pneumothorax
7	- AF - AV- junctional rhythm	normal TEE	no	<i>immunosuppressant</i> hydrocortisone <i>anti-hypotensive</i> soprenalin/noradrenalin  CVVHD
8	- Sinus rhythm - Right bundle branch block - Low voltages I- aVF	n.a.	no	<i>antibiotics</i> ciproxin/ceftriaxone <i>immunosuppressant</i> prednisone