



## UvA-DARE (Digital Academic Repository)

### Angiogenesis inhibition in high grade glioma

Verhoeff, J.J.C.

**Publication date**  
2009

[Link to publication](#)

#### **Citation for published version (APA):**

Verhoeff, J. J. C. (2009). *Angiogenesis inhibition in high grade glioma*. [Thesis, fully internal, Universiteit van Amsterdam].

#### **General rights**

It is not permitted to download or to forward/distribute the text or part of it without the consent of the author(s) and/or copyright holder(s), other than for strictly personal, individual use, unless the work is under an open content license (like Creative Commons).

#### **Disclaimer/Complaints regulations**

If you believe that digital publication of certain material infringes any of your rights or (privacy) interests, please let the Library know, stating your reasons. In case of a legitimate complaint, the Library will make the material inaccessible and/or remove it from the website. Please Ask the Library: <https://uba.uva.nl/en/contact>, or a letter to: Library of the University of Amsterdam, Secretariat, P.O. Box 19185, 1000 GD Amsterdam, The Netherlands. You will be contacted as soon as possible.

# Chapter 5.

**Tumor control by whole brain irradiation  
of anti-VEGF-treated mice bearing  
intracerebral glioma**

## Tumour control by whole brain irradiation of anti-VEGF-treated mice bearing intracerebral glioma

Joost J.C. Verhoeff<sup>a,b</sup>, Lukas J.A. Stalpers<sup>a</sup>, An Claes<sup>c</sup>, Koos E. Hovinga<sup>d</sup>,  
Gijsbert D. Musters<sup>b</sup>, W. Peter Vandertop<sup>e</sup>, Dick J. Richel<sup>b</sup>,  
William P.J. Leenders<sup>c</sup>, Wouter R. van Furth<sup>e,\*</sup>

<sup>a</sup> Academic Medical Center, Department of Radiation Oncology, Amsterdam, The Netherlands

<sup>b</sup> Laboratory for Experimental Oncology and Radiobiology, Center for Experimental Molecular Medicine, Amsterdam, The Netherlands

<sup>c</sup> Radboud University Nijmegen Medical Center, Department of Pathology, Nijmegen, The Netherlands

<sup>d</sup> Memorial Sloan-Kettering Cancer Center, Department of Neurosurgery, New York, NY, USA

<sup>e</sup> Neurosurgical Center Amsterdam, Academic Medical Center, Amsterdam, The Netherlands

### ARTICLE INFO

#### Article history:

Received 28 April 2009

Received in revised form 23 July 2009

Accepted 6 August 2009

Available online xxxx

#### Keywords:

Anti-angiogenesis

Pegaptanib

Irradiation

Orthotopic

Glioma

### ABSTRACT

**Aim of the study:** Tumour angiogenesis and invasion are key features of glioblastoma multiforme (GBM). Angiogenesis inhibitors increase progression-free survival (PFS) of recurrent GBM patients. VEGF inhibition controls the bulk tumour growth by inhibition of angiogenesis, but does not inhibit the invasive tumour component. We investigated if invasive tumour growth can be controlled by combining anti-VEGF treatment with irradiation of tumour plus surrounding brain in an orthotopic murine model for GBM.

**Methods and materials:** GBM cell line U251-NG2 was inoculated through a guide screw in the right frontal lobe of 53 athymic nude mice. Pegaptanib (a slow-releasing aptamer against VEGF) was injected in the tumour bed either or not followed by irradiation treatment with implanted I-125 seeds. Pegaptanib and/or irradiation were compared with sham-treated controls, resulting in four groups of 10–15 mice each. After 6 weeks of treatment, histological analysis was performed on all brains.

**Results:** VEGF inhibition by locally deposited pegaptanib decreased tumour blood vessel density, and increased tumour hypoxia. Pegaptanib treatment still allowed the formation of tumour satellites. Irradiation decreased tumour size and suppressed formation of satellites. Combined pegaptanib plus irradiation further increased PFS. Tumour size directly correlated with PFS.

**Concluding statement:** The anti-tumour effects of local VEGF inhibition are partially circumvented by the formation of invasive tumour satellites. Additional irradiation is effective in slowing down proliferation of these invasive tumour components.

© 2009 Elsevier Ltd. All rights reserved.

## 1. Introduction

Glioblastoma multiforme (GBM) accounts for about one third of all the intracranial tumours and is one of the most aggres-

sive brain tumours. The tumour bulk consists of a necrotic core surrounded by a highly angiogenic rim, providing a rationale for anti-angiogenesis as anti-GBM treatment. Another hallmark of this malignant tumour is the extensive migration

\* Corresponding author. Address: 1105 AZ Amsterdam, The Netherlands. Tel.: +31 20 5669111; fax: +31 20 6091278.

E-mail addresses: j.j.verhoeff@amc.nl (J.J.C. Verhoeff), w.r.vanfurth@amc.uva.nl (W.R. van Furth).

0959-8049/\$ - see front matter © 2009 Elsevier Ltd. All rights reserved.

doi:10.1016/j.ejca.2009.08.004

of cancer cells that can intrude even into the contralateral hemisphere.<sup>1,2</sup> Conventional treatment of GBM consists of surgical resection of the tumour bulk followed by radiotherapy and chemotherapy. Despite modern treatments, these high-grade glial tumours virtually always recur.<sup>3</sup> In contrast to three decades of minimal clinical improvements, the recent clinical trials that combine angiogenesis inhibition with chemotherapy show a hopeful increase of progression-free survival (PFS).<sup>4</sup> Anti-angiogenic therapies mainly aim at neutralising vascular endothelial growth factor-A (VEGF-A), e.g. by bevacizumab.<sup>5</sup> VEGF-A is a potent inducer of vascular hyperpermeability<sup>6</sup> and, in the context of brain tumours, of cerebral oedema. Therefore the beneficial effects of angiogenesis inhibition on PFS are likely, at least in part, attributable to a reduction of oedema.<sup>7</sup>

Although anti-VEGF treatment shows promising results for a number of extracranial tumour types,<sup>8</sup> the special environment of the brain appears to allow escape (to some extent) from such therapies. The brain is a densely vascularised organ that allows angiogenesis-independent tumour progression by cooption of brain vessels. *In vivo* brain tumour models and histological evaluation of patient autopsy material indeed showed that, despite effective reduction of angiogenic growth patterns, invasion continues under angiogenesis inhibition.<sup>9,10</sup>

Cancer cells behind the intact blood brain barrier (BBB) of incorporated pre-existing brain vessels are less susceptible to chemotherapy.<sup>11</sup> Since brain irradiation causes a disruption of the BBB,<sup>12</sup> it may enhance the efficacy of chemotherapy. BBB disruption may last up to 1 month after irradiation, thereby creating a window for additional therapy.<sup>13</sup>

Besides disruption of the BBB, radiation treatment triggers cell death by apoptosis but also upregulates VEGF-A expression.<sup>14</sup> VEGF-A may in turn induce AKT activation in endothelial cells, conferring resistance of these cells to radiation-induced apoptosis.<sup>15</sup> Anti-VEGF therapy may therefore enhance efficacy of radiation therapy. Furthermore, although the highly invasive tumour areas in glial tumours can escape anti-angiogenic therapy and high dose radiation treatment, tumour cells in these areas are predicted to be susceptible to low dose radiation-induced damage,<sup>16</sup> providing a further rationale for combining anti-angiogenic therapy with low dose irradiation.

In this study we tested the effects of combined treatment with angiogenesis inhibitors and radiation on the angiogenic tumour component and on the invasive component. Whole brain irradiation with generous boosting fields would, theoretically, be best to attack all invasive tumour components.<sup>1</sup> To mimic this clinical setting *in vivo*, we based our *in vivo* experiments on an intracranial irradiation model without lethal side-effects.<sup>17</sup>

To avoid systemic side-effects of angiogenesis inhibitors, which can be severe,<sup>18</sup> we chose to treat GBM locally. Local treatment of GBM with chemotherapy is already in clinical practice, e.g. with implantation of chemotherapy wafers during surgery shortly after resection,<sup>19</sup> or adjuvant through an Ommaya reservoir.<sup>20</sup> Here we mimicked this situation and injected a slow-releasing angiogenesis inhibitor into the tumour area.

## 2. Materials and methods

### 2.1. Cell line

The human glioblastoma cell line U251-NG2 is a transfected U251 line that overexpresses glial precursor proteoglycan NG2. NG2 expression increases proliferation, migration and chemoresistance *in vitro* and overexpression promotes tumour angiogenesis and growth rates *in vivo*.<sup>20</sup> In the mouse brain, this cell line gives rise to invasive, highly vascular tumours,<sup>22</sup> making it an excellent cell line to concurrently study angiogenesis and brain invasion. Furthermore, this GBM cell line is highly radioresistant,<sup>23</sup> thereby reflecting clinical GBM growth and treatment response. The cells were cultured<sup>21</sup> and xenotransplanted into the nude mouse brains as described previously.<sup>17</sup>

### 2.2. Orthotopic murine model

Athymic Nude-*nu* female mice (Harlan, Horst, The Netherlands), 4–6 weeks of age, were kept under specific pathogen-free conditions according to stringent experimental animal facility regulations. Gliomas were xenografted orthotopically as previously described.<sup>17</sup> In short, at day –28 (day 0 is start of therapies) we implanted a hollow guide-screw right frontolateral in the skull of 53 mice. At day –7 we slowly injected a suspension of 3  $\mu$ l PBS with  $5 \times 10^5$  tumour cells at 2 mm below the screw. All mouse experiments were approved, monitored and reviewed by the university committee on animal experiments.

### 2.3. Treatment regimens

Anti-angiogenesis treatment started shortly prior to radiotherapy. Pegaptanib is a 28-base RNA aptamer against VEGF<sub>165</sub>, approved for treatment of age-related macular degeneration.<sup>24</sup> The aptamer is covalently linked to two branched 20-kD polyethylene glycol moieties. To prolong activity at the site of action, the sugar backbone of pegaptanib was modified to prevent degradation by endogenous endonucleases and exonucleases, and the polyethylene glycol moieties were added to increase the half-life of the drug.<sup>25</sup> After local intravitreal injection of these microbeads, the active substance is released for a period of at least 3 weeks and is applied every 6 weeks in ophthalmology.<sup>24,26</sup> Pegaptanib (~10  $\mu$ g in 3  $\mu$ l) was slowly injected through the hollow screw into the tumour bed. Half of the mice received sham injections with PBS.

Subsequently in the same surgical session, a 1 mCi iodine-125 (<sup>125</sup>I) seed was inserted through the hollow screw as described before.<sup>17</sup> Compared to external beam irradiation, the brachytherapy technique allows high-dose local irradiation of the experimental tumour with lower dose on adjacent normal mouse brain, and reduces inadvertent irradiation of the pharynx. This enables to study the effects of extended irradiation on tumour and brain. The <sup>125</sup>I seeds (IBt, Seneffe, Belgium) delivered a minimal dose of 8 Gy in 6 weeks at 5 mm below the seed. More closely to the seed at 2.5 mm the dose was 21.5 Gy; at 10 mm distance the ‘pharynx dose’ was

2.4 Gy. Randomly, half of the mice from the pegaptanib and control groups received  $^{125}\text{I}$  seeds; in the remaining mice, inactive 'sham' seeds were inserted, resulting in 4 treatment groups. Treatment S ( $n = 11$ ) consisted of sham treatments; treatment P ( $n = 12$ ) combined sham seeds with pegaptanib therapy; treatment I ( $n = 15$ ) comprised  $^{125}\text{I}$  radiotherapy plus control injections; and treatment C ( $n = 15$ ) consisted of irradiation combined with pegaptanib injection. We hypothesised to find an additive treatment effect on progression of 20–30%. With a power of 80% and a predicted standard deviation of 3 days, group size should be 7–14 mice. We expected the difference between irradiation and combined treatments to be around 20%, therefore more mice were randomised into these groups.

The animals were sacrificed when signs of progression occurred or after 6 weeks of treatment in case of no obvious progression. Progression was defined as weight loss exceeding 20%, or physical and neurological signs indicating tumour growth-like posture changes, diminished activity, diminished skin turgor, rotational behaviour and a domehead – a phenomenon of skull expansion by extreme tumour growth. Weight was determined every 3 days or daily when over 10% weight was lost. Brains were harvested and formalin-fixed and paraffin-embedded, or fresh-frozen. In addition, to analyse pegaptanib concentrations of three randomly chosen sham-treated mice and five pegaptanib-treated or combined-treated mice brains were cut through the injection site. One half was formalin-fixed, whereas the other half was fresh-frozen to enable analysis of pegaptanib concentrations.

#### 2.4. Immunochemical and immunohistochemical analysis

All histological analyses were performed on blindly coded material. Formalin-fixed, paraffin-embedded tissue blocks were entirely sectioned axially (section thickness  $8\ \mu\text{m}$ ) for histological and immunohistochemical analysis. Each twentieth section was stained with Nissl (Cresylechtviolet; Sigma-Aldrich, Zwijndrecht, The Netherlands). The section with the maximal cross-sectional size of the tumour was used to calculate the percentage tumour area as  $\frac{\text{tumour area}}{\text{total brain area}} * 100$ .

Additional analysis was performed on axial sections immediately following the one with the largest tumour area. Nissl-stained sections were used to count mitotic figures present in 3 randomised high power fields (hpfs) and established the Nissl mitosis index. Necrosis in the tumour area was scored in Nissl-stained sections semi-quantitatively using the grading 'none (0), <20% (1), 20–70% (2) and >70% (3)'. Satellite tumours were defined as clusters of tumour cells sized over  $200\ \mu\text{m}$  at distance  $>200\ \mu\text{m}$  from the original tumour, and were counted in the sections with the largest tumour area. Proliferation was scored on Ki-67-stained sections (Clone SP6, Lab Vision Corporation, Fremont, CA, USA), using the grading 'none (0), <20% (1), 20–70% (2) and >70% (3)'. Tumour hypoxia was assessed in Glut1-stained sections (Dako™, Glostrup, Denmark) and was scored as, not present (0) or present (1). In addition, intratumoural blood vessel-like structures were considered present (1) or not present (0) when stained with Glut1 and were considered present (1) or not present (0) when stained with CD34 (anti-mouse CD34; Cedarlane™, Burlington, Canada). IgG-stained sections

(Vector Laboratories™, Burlingame, CA, USA) were scored to assess leakiness of vessels; no leakage (0), somewhat leaky (1) or severely leaky (2).

Eight fresh-frozen brains were analysed for residual pegaptanib concentrations. Concentration of anti-VEGF aptamer in tissues was determined by dual hybridisation as described previously (United States Patent Application 20070178476).

#### 2.5. Data analysis

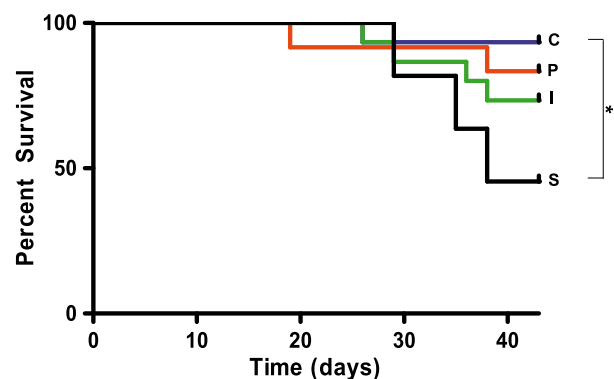
Differences were analysed using the unpaired t-test for equality of means when the data were distributed normally, using Prism 4.03® software (Graphpad™, La Jolla, CA, USA), or the Wilcoxon log rank test when the data were not distributed normally, using SPSS© software (SPSS™, Chicago, IL, USA). For analysis of repetitive weight measurements data we performed ANOVA followed by Tukey's post hoc test. The differences were considered significant when  $p < 0.05$ .

### 3. Results

#### 3.1. Progression-free survival

PFS of the tumour-bearing mice was defined as 'no neurological or physical signs of illness, and not more than 20% decrease in weight below baseline level'. Compared to all other groups, sham-treated mice showed the least decline in weight (Fig. S1). The mean weight of irradiated mice declined more than that of pegaptanib-treated mice, and combined-treated mice maintained weight better than irradiated mice. Six untreated mice (55%) progressed within 6 weeks; almost 35% of mice receiving irradiation (5/15) also showed signs of progression (Fig. 1). Mice treated with pegaptanib or the combination of pegaptanib and irradiation showed lower progression rates (17% and 7%, respectively) (Fig. 1).

All progression-free mice were sacrificed after 6 weeks of treatment while treatment was still ongoing. This time point



**Fig. 1 – Progression-free survival Kaplan-Meier curve for the four treatment groups receiving sham (S, black curve), pegaptanib (P, red curve), irradiation (I, green curve) and combination (C, blue curve) treatments. Combined-treated mice had significant better survival than sham-treated ( $p < 0.05$ ). Pegaptanib showed a trend of improvement compared to sham treatment ( $p < 0.07$ ).**

was chosen because it is approximately three times the half-life of pegaptanib. No systemic diseases were observed at autopsy. Analysis of the mouse brains showed tumours in approximately 91% of untreated mice (10/11), 92% of pegaptanib-treated mice (11/12) and 40% of the irradiated mice (6/15). In 33% of the combined-treated mice (5/15) tumours or remnants of tumours were present. All but one progressed mice indeed had tumours or tumour remnants; in progression-free mice in the irradiation group, tumour presence was approximately 20% (Fig. 2a).

Examination of the fresh-frozen brains revealed that 0.3  $\mu$ g pegaptanib was present on average per gram mouse brain after single injection 6 weeks earlier. In examined sham-treated brains, no pegaptanib was detected.

### 3.2. VEGF inhibition versus sham treatment

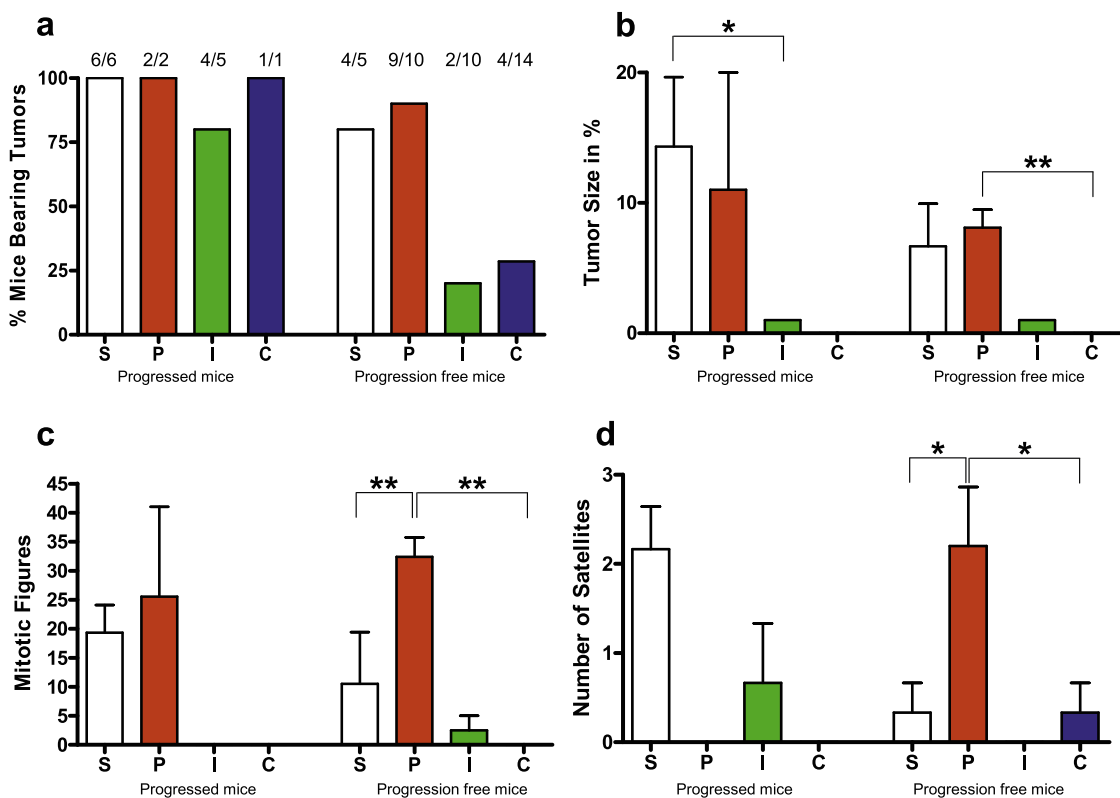
Pegaptanib-treated tumours presented with similar sizes and numbers of mitotic figures as sham-treated mice (Fig. 2b). The extent of necrosis and the proliferation index were comparable in both groups, also in subgroup analyses. VEGF inhibition led to decrease of Glut1 and CD34-positive blood vessels

( $p < 0.04$ ) and an increase of hypoxia (Glut1 positive tumour cells) in these tumours ( $p < 0.02$ ).

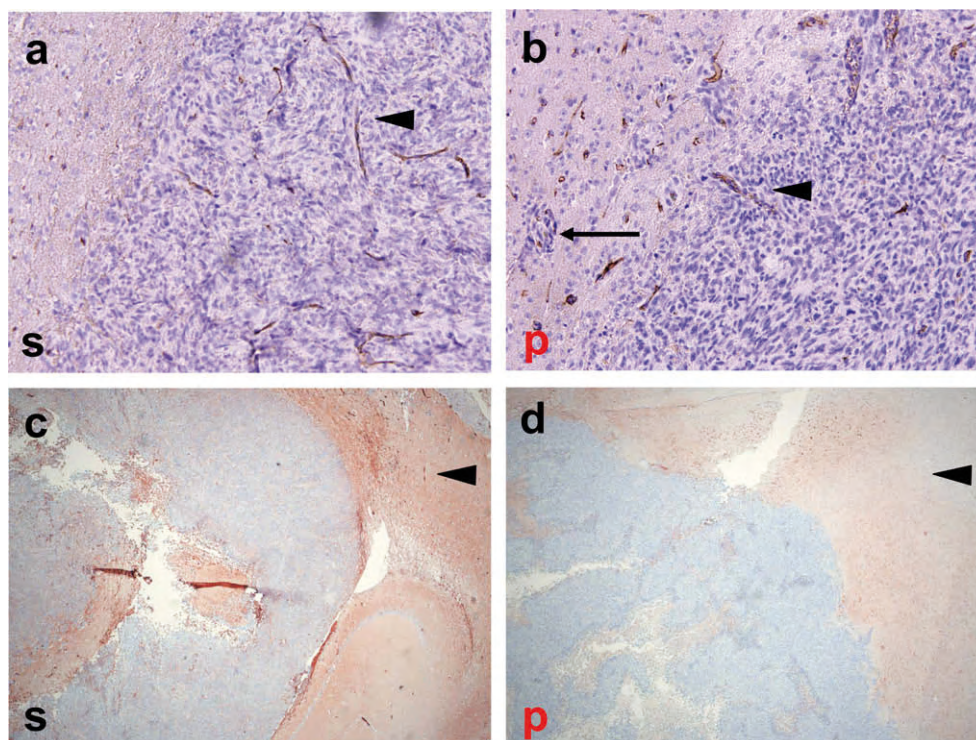
A more extended analysis on subgroups of progression-free or progressed mice revealed that progressed pegaptanib-treated mice had diminished leakage of IgG compared to progressed controls ( $p < 0.04$ ). Compared to tumours of sham-treated mice, the tumours of progression-free pegaptanib-treated mice showed a higher number of mitotic figures ( $p < 0.02$ ) (Fig. 2c) and an increased formation of satellites around the primary tumour site ( $p < 0.04$ ) (Fig. 2d).

### 3.3. Irradiated mice and combined-treated mice

In 60% of irradiated mice, no tumours or tumour remnants could be detected. In case tumours were detected, tumour size was strongly reduced (Fig. 2a and b). There were no satellites surrounding the primary tumour sites after irradiation (Fig. 2d). Mitotic cell numbers and proliferation index were low compared to all non-irradiated mice, and necrosis was lower than in pegaptanib-treated mice. No tumour hypoxia was found, and no tumour vessels expressing CD34 or Glut1 were detected (Fig. 3b). For irradiated mice with tumour



**Fig. 2 – Histological data for the 4 treatment groups receiving sham (S, white), pegaptanib (P, red), irradiation (I, green) and combination (C, blue) treatments. (a) Histological tumour-take in all groups (total group size above bars). Left-hand side 4 bars are of progressed mice: sham (S, white, n = 6), pegaptanib (P, red, n = 2), irradiation (I, green, n = 5) and combination (C, blue, n = 1) treatments. Right-hand side 4 bars are of progression-free mice. Sham (S, white, n = 5), pegaptanib (P, red, n = 10), irradiation (I, green, n = 11) and combination (C, blue, n = 14) treatments. (b) Size of tumours in percentage of total brain area on the section with largest diameter, of progressed and progression-free mice with tumour remnants present ( $p < 0.05$ ,  $^{**}p < 0.02$ ). (c) Mitotic figure numbers in progressed and progression-free mice ( $^{*}p < 0.02$ ) (d) Formation of satellites in progressed and progression-free mice ( $^{*}p < 0.05$ ).**



**Fig. 3 – Effect of anti-angiogenic treatment on mice carrying intracerebral GBM tumours. (a and b) H&E-CD34 immunohistochemical stainings of intracerebral U251-NG2 lesions of vehicle-treated (s) and pegaptanib-treated (p) mice. VEGF inhibition by locally deposited pegaptanib decreased tumour blood vessel density (arrowheads) and increased invasiveness of the tumour (arrow pointing at a micrometastasis in the invasive front; not scored as satellite). (c and d) IgG staining (brown, arrowheads), compared to vehicle-treated animals (s), showed a decreased tumour leakage (arrowheads) in pegaptanib-treated animals (p). The shown stainings were performed on mice that lived for 5 weeks (a, c, d) and 6 weeks (b), respectively.**

remnants, there was a trend towards a lower IgG leakage compared to control animals.

Almost all *combination-treated* animals were sacrificed without signs of progression (Fig. 2a). There were only very small tumour remnants present in the combination-treated mice; therefore only few proliferating cells and some necrosis were detectable, but no hypoxia, Glut1 or CD34-positive blood vessels (Fig. 2c). Leakiness of the blood vessels as measured by IgG efflux did not differ between the combined treatment group and irradiated animals. Tumour size of the only progressed mouse was equal to that of mice that progressed under irradiation treatment, and comparable numbers of satellites were present (Fig. 2b and d).

#### 4. Discussion

The purpose of this investigation was to study whether irradiation synergises with anti-VEGF treatment in an orthotopic mouse model of GBM. We were particularly interested in the combined effect of anti-angiogenesis and irradiation on tumour invasion into the brain. To enable histological analysis of the brain tissue, we sacrificed all remaining progression-free mice after 6 weeks of treatment, when both treatment modalities are still active. A later time point would inevitably lead to diluted histological findings. Interestingly, locally deposited pegaptanib inhibited local tumour growth, but did

not inhibit tumour invasion in the brain, in agreement with angiogenesis-independent tumour infiltration. We found that irradiation produced significant additional anti-tumour effects, also against tumour satellites.

Clinical trials with VEGF inhibition in recurrent GBM patients showed reduced MR contrast enhancement of tumour and a considerable increase in PFS.<sup>4,27</sup> Regardless of the preliminary ending after 6 weeks of treatment for histological analysis, we also presume improvement of PFS in our mice treated by the anti-VEGF aptamer pegaptanib alone. However, we found a more invasive growth pattern, scored as an increased satellite formation. This corroborates recent clinical data showing that VEGF-antibody bevacizumab suppresses recurrence of the hypervascularised enhancing tumour parts more effectively than of the non-enhancing, infiltrative tumour extension.<sup>28</sup>

One of the key mechanisms of VEGF inhibition is vessel normalisation, thus creating a window of improved perfusion, followed by pruning of newly formed vessels in non-CNS tumours.<sup>29</sup> We evaluated the effects of VEGF inhibition at a time point after the described window of vascular normalisation,<sup>30</sup> and observed less tumour vessels and an increased amount of tumour hypoxia in pegaptanib-treated mice, indicating that indeed tumour vessels were pruned by VEGF inhibition. In mice with tumour progression, we found VEGF inhibition does lead to diminished vascular leakage as

measured by efflux of IgG. This observation agrees with the previous findings with other VEGF inhibitors.<sup>31</sup> In the subgroup of progression-free pegaptanib-treated mice, the mitotic activity was higher, as was the level of hypoxia in the tumour. The higher level of hypoxia in the bulk tumour suggests that pegaptanib is still effective after 3 half-times, indicating also a possible clinical feasibility. An increased mitotic activity was observed in the invasive tumour compartments: we found an increased formation of satellites surrounding the primary tumour site in animals that were analysed after 6 weeks, but not in animals that progressed earlier. This could indicate that local outgrowth of the primary tumour is stalled by pegaptanib, creating time for formation of satellites. Sequence of treatments is an important factor for outcome of combined anti-angiogenesis and irradiation treatment. In a non-small-cell lung carcinoma mouse model concurrent ZD6474 anti-angiogenic treatment produced some enhancement of fractionated radiotherapy, whereas sequential administration led to a highly significant interaction between these modalities.<sup>32</sup> Therefore, further investigations on sequence of treatments are warranted.

We observed that combined irradiation of the tumour plus surrounding normal brain not only reduces tumour bulk growth and increases PFS, but also suppresses invasive growth. Combined treatment was well tolerated by the animals, the weight loss that occurred in irradiated animals was not observed in combined-treated animals. Nevertheless, in this experiment, tumour control by radiotherapy was too strong to enable the analysis of vasculature and intratumoural parameters; further research is necessary (for instance with a delayed start of treatments) to enable such analysis.

In contrast to the observed repression of invasive components by irradiation, some studies show that low-dose irradiation can lead to more invasion and satellite formation.<sup>33,34</sup> This more invasive phenotype may be attributed to the fact that low-dose irradiation leads to selection of a more glioma cancer stem cell-like phenotype.<sup>35</sup> To prevent this, it is crucial to apply a clinically relevant radiation dose in murine models, as we used in this study.

In the past 20–30 years, more precise CT and MR imaging of gliomas has enabled the reduction of irradiation volumes from whole brain irradiation to even smaller and more precisely targeted volumes. Nowadays GBMs that are treated by radiotherapy typically have a radiation field with a 2-cm margin around the enhancing tumour.<sup>36</sup> Although treatment with irradiation in combination with chemotherapy and/or VEGF inhibitors may allow good local tumour control, this may not apply to the development of distant satellites.<sup>28</sup> We indeed found that long-term GBM survivors with a recurrent GBM have tumours that are genotypically identical to the primary GBM.<sup>37</sup> This new situation forms the next frontier in the goal to control the invasive tumour compartment, now that oedema and other features of the primary tumour can be better controlled. Nowadays angiogenesis inhibition is often used to treat recurrent GBM; we were interested in additive treatments for invasive components. For primary GBM, irradiation combined with temozolomide is the standard treatment.<sup>3</sup> Adding anti-angiogenic treatment to the primary GBM regimen could also be fruitful although toxicities (e.g. intratumoural haemorrhage, wound dehiscence and bowel

perforation) and patterns of relapse (e.g. satellite formation) need to be monitored closely.<sup>38,39</sup> Promising combinatory strategies for GBM can prevent invasive growth, as it was shown that combined bevacizumab plus anti-IL6 therapy was significantly more efficient than monotherapy at inhibiting the growth and invasion of aggressive experimental glioma *in vivo*.<sup>40</sup>

Our preclinical study shows that when VEGF inhibition is combined with irradiation of the tumour plus surrounding brain, tumour growth is delayed and invasion is suppressed. Whole brain irradiation with generous boosting fields would theoretically be best to attack all invasive tumour components. To minimise late radiation toxicity, better imaging techniques (like MRSI) are required to visualise the invasive tumour components and enable more precise treatment with irradiation.<sup>41,42</sup> Especially in more distant areas, an increase in the permeability of the BBB that allows for additive treatments could be of great benefit.

---

### Conflict of interest statement

None declared.

---

### Acknowledgements

The authors thank G.S. Robinson from Eyetech/Pfizer™ for freely providing pegaptanib. They also thank G. Sennello, A.H. van der Kracht and M.D. Ramkema for excellent support in the histological analysis, J. Wing for analysing the pegaptanib levels in brain tissue and Dr. Martha Chekenya for providing cell line U251-NG2.

---

### Appendix A. Supplementary data

Supplementary data associated with this article can be found, in the online version, at doi:10.1016/j.ejca.2009.08.004.

---

### REFERENCES

1. Salazar OM, Rubin P, Feldstein ML, Pizzutiello R. High dose radiation therapy in the treatment of malignant gliomas: final report. *Int J Radiat Oncol Biol Phys* 1979;5:1733–40.
2. Giese A, Bjerkvig R, Berens ME, Westphal M. Cost of migration: invasion of malignant gliomas and implications for treatment. *J Clin Oncol* 2003;21:1624–36.
3. van den Bent MJ, Hegi ME, Stupp R. Recent developments in the use of chemotherapy in brain tumours. *Eur J Cancer* 2006;42:582–8.
4. Vredenburgh JJ, Desjardins A, Herndon JE, et al. Bevacizumab plus irinotecan in recurrent glioblastoma multiforme. *J Clin Oncol* 2007;25:4722–9.
5. Folkman J. New perspectives in clinical oncology from angiogenesis research. *Eur J Cancer* 1996;32A:2534–9.
6. Dvorak HF. Vascular permeability factor/vascular endothelial growth factor: a critical cytokine in tumor angiogenesis and a potential target for diagnosis and therapy. *J Clin Oncol* 2002;20:4368–80.
7. Batchelor TT, Sorensen AG, di Tomaso E, et al. AZD2171, a pan-VEGF receptor tyrosine kinase inhibitor, normalizes

- tumor vasculature and alleviates edema in glioblastoma patients. *Cancer Cell* 2007;11:83–95.
8. Eskens FA, Sleijfer S. The use of bevacizumab in colorectal, lung, breast, renal and ovarian cancer: where does it fit? *Eur J Cancer* 2008;44:2350–6.
  9. Rubenstein JL, Kim J, Ozawa T, et al. Anti-VEGF antibody treatment of glioblastoma prolongs survival but results in increased vascular cooption. *Neoplasia* 2000;2:306–14.
  10. Leenders WP, Kusters B, Verrijp K, et al. Antiangiogenic therapy of cerebral melanoma metastases results in sustained tumor progression via vessel co-option. *Clin Cancer Res* 2004;10:6222–30.
  11. Muldoon LL, Soussain C, Jahnke K, et al. Chemotherapy delivery issues in central nervous system malignancy: a reality check. *J Clin Oncol* 2007;25:2295–305.
  12. Chang CH, Horton J, Schoenfeld D, et al. Comparison of postoperative radiotherapy and combined postoperative radiotherapy and chemotherapy in the multidisciplinary management of malignant gliomas. A joint radiation therapy oncology group and eastern cooperative oncology group study. *Cancer* 1983;52:997–1007.
  13. Cao Y, Tsien CI, Shen Z, et al. Use of magnetic resonance imaging to assess blood-brain/blood-glioma barrier opening during conformal radiotherapy. *J Clin Oncol* 2005;23:4127–36.
  14. Nordal RA, Wong CS. Molecular targets in radiation-induced blood-brain barrier disruption. *Int J Radiat Oncol Biol Phys* 2005;62:279–87.
  15. Wachsberger P, Burd R, Dicker AP. Tumor response to ionizing radiation combined with antiangiogenesis or vascular targeting agents: exploring mechanisms of interaction. *Clin Cancer Res* 2003;9:1957–71.
  16. Williams JR, Zhang Y, Zhou H, et al. Overview of radiosensitivity of human tumor cells to low-dose-rate irradiation. *Int J Radiat Oncol Biol Phys* 2008;72:909–17.
  17. Verhoeff JJ, Stalpers LJ, Coumou AW, et al. Experimental iodine-125 seed irradiation of intracerebral brain tumors in nude mice. *Radiat Oncol* 2007;2:38.
  18. Eskens FA, Verweij J. The clinical toxicity profile of vascular endothelial growth factor (VEGF) and vascular endothelial growth factor receptor (VEGFR) targeting angiogenesis inhibitors; a review. *Eur J Cancer* 2006;42:3127–39.
  19. Mitchell P, Ellison DW, Mendelow AD. Surgery for malignant gliomas: mechanistic reasoning and slippery statistics. *Lancet Neurol* 2005;4:413–22.
  20. Ommaya AK, Rubin RC, Henderson ES, et al. A new approach to the treatment of inoperable brain tumors. *Med Ann Dist Columbia* 1965;34:455–8.
  21. Chekenya M, Hjelstuen M, Enger PO, et al. NG2 proteoglycan promotes angiogenesis-dependent tumor growth in CNS by sequestering angiostatin. *FASEB J* 2002;16:586–8.
  22. Brekke C, Lundervold A, Enger PO, et al. NG2 expression regulates vascular morphology and function in human brain tumours. *Neuroimage* 2006;29:965–76.
  23. Hovinga KE, Stalpers LJ, van Bree C, et al. Radiation-enhanced vascular endothelial growth factor (VEGF) secretion in glioblastoma multiforme cell lines – a clue to radioresistance? *J Neurooncol* 2005;74:99–103.
  24. Gragoudas ES, Adamis AP, Cunningham Jr ET, Feinsod M, Guyer DR. Pegaptanib for neovascular age-related macular degeneration. *N Engl J Med* 2004;351:2805–16.
  25. Ruckman J, Green LS, Beeson J, et al. 2'-Fluoropyrimidine RNA-based aptamers to the 16S-amino acid form of vascular endothelial growth factor (VEGF165). Inhibition of receptor binding and VEGF-induced vascular permeability through interactions requiring the exon 7-encoded domain. *J Biol Chem* 1998;273:20556–67.
  26. Schmidt PG, Campbell KM, Hinds KD, Cook GP. PEGylated bioactive molecules in biodegradable polymer microparticles. *Expert Opin Biol Ther* 2007;7:1427–36.
  27. Cloughesy TF, Prados MD, Wen PY, et al. A phase II, randomized, non-comparative clinical trial of the effect of bevacizumab (BV) alone or in combination with irinotecan (CPT) on 6-month progression free survival (PFS6) in recurrent, treatment-refractory glioblastoma (GBM). *J Clin Oncol* 2008;26(May 20 Suppl.):2010b.
  28. Norden AD, Young GS, Setayesh K, et al. Bevacizumab for recurrent malignant gliomas: efficacy, toxicity, and patterns of recurrence. *Neurology* 2008;70:779–87.
  29. Jain RK. Normalization of tumor vasculature: an emerging concept in antiangiogenic therapy. *Science* 2005;307:58–62.
  30. Tong RT, Boucher Y, Kozin SV, Winkler F, Hicklin DJ, Jain RK. Vascular normalization by vascular endothelial growth factor receptor 2 blockade induces a pressure gradient across the vasculature and improves drug penetration in tumors. *Cancer Res* 2004;64:3731–6.
  31. Claes A, Gambarota G, Hamans B, et al. Magnetic resonance imaging-based detection of glial brain tumors in mice after antiangiogenic treatment. *Int J Cancer* 2008;122:1981–6.
  32. Williams KJ, Telfer BA, Brave S, et al. ZD6474, a potent inhibitor of vascular endothelial growth factor signaling, combined with radiotherapy: schedule-dependent enhancement of antitumor activity. *Clin Cancer Res* 2004;10:8587–93.
  33. Wild-Bode C, Weller M, Rimner A, Dichgans J, Wick W. Sublethal irradiation promotes migration and invasiveness of glioma cells: implications for radiotherapy of human glioblastoma. *Cancer Res* 2001;61:2744–50.
  34. Tabatabai G, Frank B, Wick A, et al. Synergistic anti glioma activity of radiotherapy and enzastaurin. *Ann Neurol* 2007;61:153–61.
  35. Bao S, Wu Q, Sathornsumetee S, et al. Stem cell-like glioma cells promote tumor angiogenesis through vascular endothelial growth factor. *Cancer Res* 2006;66:7843–8.
  36. Hochberg FH, Pruitt A. Assumptions in the radiotherapy of glioblastoma. *Neurology* 1980;30:907–11.
  37. van Nifterik KA, Elkhuizen PH, van Andel RJ, et al. Genetic profiling of a distant second glioblastoma multiforme after radiotherapy: recurrence or second primary tumor? *J Neurosurg* 2006;105:739–44.
  38. Narayana A, Kelly P, Golfinos J, et al. Antiangiogenic therapy using bevacizumab in recurrent high-grade glioma: impact on local control and patient survival. *J Neurosurg* 2009;110:173–80.
  39. Gutin PH, Iwamoto FM, Beal K, et al. Safety and efficacy of bevacizumab with hypofractionated stereotactic irradiation for recurrent malignant gliomas. *Int J Radiat Oncol Biol Phys* 2009.
  40. Saidi A, Hagedorn M, Allain N, et al. Combined targeting of interleukin-6 and vascular endothelial growth factor potentially inhibits glioma growth and invasiveness. *Int J Cancer* 2009;125:1054–64.
  41. Park I, Tamai G, Lee MC, et al. Patterns of recurrence analysis in newly diagnosed glioblastoma multiforme after three-dimensional conformal radiation therapy with respect to pre-radiation therapy magnetic resonance spectroscopic findings. *Int J Radiat Oncol Biol Phys* 2007;69:381–9.
  42. Stadlbauer A, Prante O, Nimsky C, et al. Metabolic imaging of cerebral gliomas: spatial correlation of changes in O-(2-18F-fluoroethyl)-L-tyrosine PET and proton magnetic resonance spectroscopic imaging. *J Nucl Med* 2008;49:721–9.

# Supplemental data

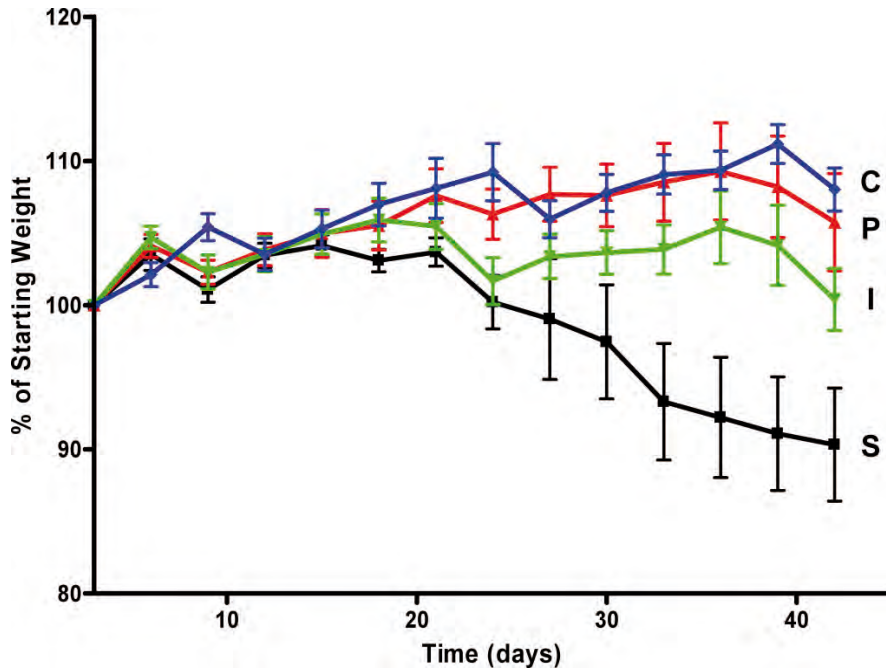


Figure S1. Pooled relative weight of untreated mice (S, black line), irradiated mice (I, green line), pegaptanib-treated mice (P, red line) and combination-treated mice (C, blue line). Postsurgery weight (day 0) is standardised to 100%. The differences are significant between the sham and the 3 other groups ( $p < 0.01$ ). Error bars display SEM.

Figure S2. Effect of anti-angiogenic treatment and irradiation on mice carrying intracerebral U251-NG2 tumours. Immunohistochemical stainings. (a) Ki-67 staining of irradiated tumour (i) with remnant proliferative cells in the irradiated area (arrowhead). (b) Glut-1 staining of irradiated tumour (i) of small size and no hypoxic areas present. (c) Ki-67 staining of pegaptanib-treated tumour (s) showing fields of invading proliferating cells (arrowhead). (d) Glut-1 staining of pegaptanib-treated tumour (p) reveals larger hypoxic areas inside the tumour bulk (arrowhead).

